

Knotting of an epidural catheter : a rare complication

H. M. ARNAOUTOGLOU, P. G. TZIMAS and G. S. PAPADOPOULOS

Abstract : Knotting of an epidural catheter leading to entrapment is a rare complication of epidural catheterization. A lumbar epidural catheter inserted in a 28-year-old woman for caesarean section anesthesia and postoperative analgesia proved difficult to remove. After multiple attempts and placing the patient in the same position as when the catheter was initially inserted, the entrapped catheter was dislodged intact, revealing a double knot near its distal tip. Leaving catheters of less than 4 cm in length in the epidural space may help to avoid this complication. It is important the patient be informed of the techniques involved in the extraction of the resistant catheter because patient's cooperation is important for the nonsurgical removal of an entrapped epidural catheter.

INTRODUCTION

The removal of an epidural catheter rarely poses any difficulty. However, a review of the literature demonstrates several complications related to the application of an epidural catheter in order to achieve epidural anaesthesia or analgesia (8, 25). Haematoma formation, catheter breakage, catheter entrapment and knot formation have been reported. Knotting of an epidural catheter is an extremely rare complication (approximately 0.0015% of all applied epidural catheters) and leads to entrapment and difficult removal (19). Thus, this situation appears to be a concern for the patient and the physician.

Here, we present a case of a difficult removal due to a looped double knotting epidural catheter in a patient who underwent a caesarian dissection with epidural anaesthesia. Furthermore, we review literature with reference to this rare complication and we suggest guidelines for removal of knotted and entrapped catheters.

CASE HISTORY

A 28 years old, 90 kg and 166 cm, primigravid woman was admitted to the obstetric department due to scheduled caesarian section in the 40th week of pregnancy because of sciatic projection. The

patient had no past medical history. The epidural space was identified at the first attempt at the L2/3 intervertebral space with the patient placed in the lateral decubitus position and using a loss-of-resistance-to-air technique with an 18 gauge Tuohy needle. An epidural catheter (PORTEX®) was inserted 6 cm beyond the needle tip, due to obesity. A test dose of 3 ml of solution lidocaine-adrenaline 2% (20 mg/ml + 5 µg/ml) was injected. Afterwards, 15 ml of solution ropivacaine 7.5 mg/ml were given bolus. The caesarian section was completed under adequate surgical anaesthesia and the catheter remained in the patient for 48 hours after the surgery so as to achieve post-operatively analgesia. Postoperative pain was controlled with a continuous epidural infusion of 10 ml of solution of ropivacaine 2 mg/ml every 8 hours and 2 mg morphine without any catheter resistance.

On postoperative day 2, the epidural anaesthetics were discontinued and removal of the catheter was attempted with the patient in sitting position. Significant resistance was encountered during the removal of the catheter, despite steady and persistent traction.

After steady and gentle traction and placing the patient in the same position as when the catheter was initially inserted, the entrapped catheter was removed intact, revealing a loop with a double knot 1 cm close to the catheter tip (Fig. 1). On follow-up, the patient had no signs of infection and no reports of neurological signs.

DISCUSSION

Eighteen cases of an entrapped epidural catheter due to a knot have been described in the

H. M. ARNAOUTOGLOU, M.D. ; P. G. TZIMAS, M.D. ; G. S. PAPADOPOULOS, M.D.

Clinic of Anaesthesia and Postoperative Intensive Care, University Hospital of Ioannina, Greece.

Correspondence address : Dr. H. M. Arnaoutoglou, Lecturer in Anesthesiology, Velissariou 60, 45221 Ioannina, Greece.

Tel. : 26510-97236. E-mail : keme42002@yahoo.gr.

Tel. : +302651049638. Fax : +302651097084.

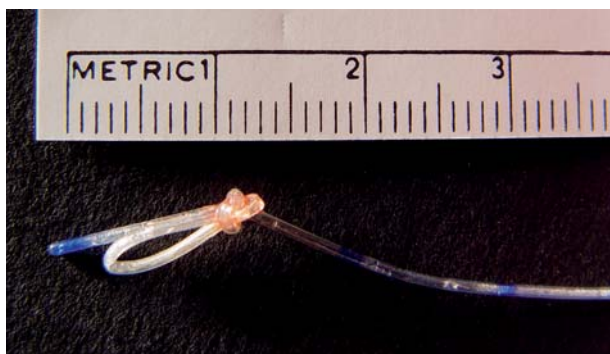


Fig. 1. — Knotted epidural catheter after removal

lumbar, caudal and thoracic region, in which various methods were used to remove the catheter (2, 4-7, 9-10, 12, 14, 16, 18, 21, 23-24, 26, 30-31).

In 12 out of 18 of these cases, the knot had been formed near the catheter tip, as in our case. 13 out of 18 involved obstetrics patients.

In 3 cases the epidural catheter was inserted in the caudal region. In 14 cases it was inserted in the lumbar region and in one case the catheter was inserted in the thoracic region. There was only one report of double-knotting of a thoracic epidural catheter.

In most cases the catheter could be pulled out by using steady and gentle traction on the first attempt.

There is one report in which removal was achieved by using general anaesthesia and neuromuscular blocking drugs (7), while in 3 other cases the catheter tip was broken and operation was necessary for removal (4, 7, 24).

Our case concerns a loop and a double-knot located 1 cm close to the catheter tip in a woman who underwent a caesarean section. The catheter was eventually removed by using steady and gentle traction after returning the patient to the position she was in at the time of insertion of the catheter.

Most authors agree that inserting the catheter less than 3-4 cm from the needle tip may prevent 180° rotation which may form a knot (17). Nevertheless, there have been reports of knotting in catheters which were inserted less than 3 cm, thus there are probably factors, other than the depth of the catheter, which may cause knotting (9, 16).

As for the maneuvers to facilitate the removal of the catheter the majority agrees that the patient should be placed in the position she was in at the time of insertion and that gentle firm traction should be applied. The traction should be discontinued only if the patient reports pain or paresthesia (15, 20). Radiological imaging with radiopaque

dye if the catheter is patent or with guidewire if the catheter is occluded is necessary in such cases. In case that Radiological imaging is not possible, Computer Tomography is required. Surgical removal would be the last choice and only after we have tried other methods. These include : 1. Placing the patient in various positions such as lateral decubitus position, sitting, kneeling with hands down and back flexed and pulling the catheter gently. 2. Filling the catheter with rapid injection of saline to increase the turgor of the catheter and lubricate it. 3. Repeating attempt after one week so as surrounding muscles and tissue are allowed to soften. If all the above methods have failed we could try to remove the catheter under general anaesthesia and neuromuscular blocking drugs (1, 3, 11, 13, 22, 27).

Surgical removal is inevitable especially when the patient is symptomatic during attempts to dislodge the catheter, when all measures have failed, and if during traction a piece of the catheter breaks and remains entrapped and the patient demonstrates neurological signs (13, 15, 28). This is why in every successful catheter removal, we should check the catheter tip and the patient should be informed if the catheter breaks while applying traction. In case of a broken catheter, the usual recommendation is to avoid surgery unless the patient demonstrates symptoms or signs. The implications due to a remaining piece of the catheter are extremely rare because of the inert nature of the epidural catheter material. Nevertheless, in the literature, one case has been described of a patient who developed stenosis in the lumbar spinal cord a year after the remaining of the epidural catheter tip in the epidural space (29).

Conclusively, in our case, after steady traction and placing the patient in the same position as when the catheter was initially inserted, we succeed in removing the entrapped catheter intact, revealing a double knot. Leaving catheters of less than 4 cm in length in the epidural space may help to avoid this complication.

Finally, it is important to inform the patient of the techniques involved in the extraction of the resistant catheter because patient's cooperation and approval are required to avoid surgical removal of an entrapped epidural catheter.

References

1. Balance J. H. W., *Difficulty in the removal of an epidural catheter*, ANAESTHESIA, **36**, 71-2, 1981.
2. Bigat Z., Borztug N., Onder G., Ertok E., *A rare complication of epidural catheter*, ACTA ANAESTHESIOL. SCAND., **49**, 589-90, 2005.

3. Blackshear R., Gravenstein N., Rodson E., *Tension applied to lumbar epidural catheters during removal is much greater with patient sitting versus lying*, ANESTHESIOLOGY, **75**, A833, 1991.
4. Blass N. H., Roberts R. B., Wiley J. K., *The case of the errant epidural catheter*, ANESTHESIOLOGY, **54**, 419-21, 1981.
5. Bromage P. R., *Epidural analgesia*. Philadelphia, Saunders, 664-6, 1978.
6. Browne R. A., Politi V. L., *Knotting of an epidural catheter, a case report*, CAN. J. ANAESTH., **26**, 142-4, 1979.
7. Chun L., Karp M., *Unusual complications from placement of catheters in caudal canal in obstetrical anesthesia*, ANESTHESIOLOGY, **27**, 96-7, 1966.
8. Cousins M. J., Veering B. T., *Epidural neural blockade*. In : Cousins M. J., Bridenbaugh P. O., eds. *Neural blockade in clinical anesthesia and management of pain*. 3rd edn. Philadelphia, Lippincott-Raven Publishers, 243-320, 1998.
9. Fibugh E. E., McNitt J. D., Cussen T., *Knotting of the Theracath™ after an uneventful epidural insertion for Cesarean delivery (Letter)*, ANESTHESIOLOGY, 1293, 1990.
10. Folk J. W., Joye T. P., Due T. A., Bailly M. K., *Epidural catheters, The long and winding road*, SOUTH MED. J., **93**, 732-3, 2000.
11. Gadalla F., *Removal of a tenacious epidural catheter*, ANESTH. ANALG., **75**, 1071-2, 1992.
12. Gozal D., Gozal Y., Beilin B., *Removal of knotted epidural catheters. Case reports*, REG. ANESTH., **21**, 71-3, 1996.
13. Gravenstein N., Blackshear R., Wissler R., *An approach to spinal or epidural catheters that are difficult to remove*, ANESTHESIOLOGY, **75**, 544, 1991.
14. Hsin S. T., Chang F. C., Tsou M. Y., Liao W. W., Lee T. Y., Lui P. W., Luk H. N., *Inadvertent knotting of a thoracic epidural catheter*, ACTA ANAESTHESIOL. SCAND., **45**, 255-7, 2001.
15. Jongleux E. F., Miller R., Freeman A., *An entrapped epidural catheter in a postpartum patient*, REG. ANESTH. PAIN MED., **23** (6), 615-7, 1998.
16. Karraz M. A., (Letter) *Knotting of an epidural catheter like a tie*, ANESTH. ANALG., **95** (1), 257, 2002.
17. Leykin Y., Lucca M., *Complications related to epidural catheter in caesarean delivery*, MINERVA ANESTESIOL., **67** (9S1), 175-80, 2001.
18. Macfarlane J., Paech M. J., *Another knotted epidural catheter*, ANESTH. INTENSIVE CARE, **30** (2), 240-3, 2002.
19. McGregor P., *A reply – knotting*, ANESTHESIOLOGY, **73**, 1923, 1990.
20. Morris G. N., Warren B. B., Hanson E. W., Mazzeo F. J., DiBenedetto D. J., *Influence of patient position on withdrawal forces during removal of lumbar extradural catheters*, ANESTHESIOLOGY, **86** (4), 778-84, 1997.
21. Nicholson M. J., Hehre F. W., Muechler H. C., *Complication associated with use of extradural catheter in obstetric anesthesia*, ANESTH. ANALG., **44**, 245-7, 1965.
22. Pasquariello C., Betz R., *A case for the removal of the retained intrathecal catheter*, ANESTH. ANALG., **72**, 562, 1991.
23. Renahan E. M., Peterson R. A., Penning J. P., Rosaeg O. P., Chow D., *Visualization of a looped and knotted epidural catheter with a guidewire*, CAN. J. ANESTH., **47**, 329-33, 2000.
24. Riegler R., Pernetzky A., *Unmovable epidural catheter due to a sling and a knot, a rare complication of epidural anesthesia in obstetrics*, REG. ANESTH., **6**, 19-21, 1983.
25. Rosenberg P. H., *Complications of catheter techniques*. In : Finucane B. T., ed. *Complications of regional anesthesia*. New York, Churchill Livingstone Inc, 220-34, 1999.
26. Saberski L. R., Schwatz J. I., Greenhouse B. B., Kennedy T. M., Ullman D. A., *A unique complication of a lumbar epidural catheter*, ANESTHESIOLOGY, **69**, 634-5, 1988.
27. Sia-Kho E., Kudlak T., *How to dislodge a severely trapped epidural catheter*, ANESTH. ANALG., **74**, 929, 1992.
28. Sidhu M. S., Asrani R. V., Bassell G. M., *An unusual complication of extradural catheterization in obstetric anaesthesia*, BR. J. ANAESTH., **55**, 473, 1983.
29. Staats P. S., Stinson M. S., Lee R. R., *Lumbar stenosis complicating retained extradural catheter tip*, ANESTHESIOLOGY, **83**, 1115-8, 1995.
30. Striebel H. W., DopJans D., *Knotting of a peridural catheter*, REG. ANAESTH., **14** (6), 104-5, 1991.
31. Stuart A. L., McDavid A. J., *Knotted epidural catheters*, REG. ANAESTH., **21**, 606, 1996.