

## Use of BIS monitor during anaesthesia of a narcoleptic patient for avoiding possible delayed emergence

Z. OZKOSE (\*), B. GUNAYDIN (\*), A. TUNGA DOGAN (\*) and R. YAVUZER (\*\*)

**Abstract :** Anaesthesia for a narcoleptic patient is not a common practice of anaesthesiologists' daily working life. Therefore special problems related to narcolepsy should be considered pre-, peroperatively and during emergence. The aim of presenting this case report is to emphasize the importance of BIS monitor use in a narcoleptic patient undergoing surgery under general anaesthesia to avoid possible prolonged emergence.

**Key words :** Anaesthesia ; narcolepsy ; BIS.

Narcolepsy refers to a syndrome of unknown origin that is characterized by abnormal sleep tendencies, including excessive daytime sleepiness and other disturbed nocturnal sleep and pathological manifestations of REM sleep (1). The underlying mechanism of this pathological condition is supposed to be the absence of neurotransmitters, normally present in the hypothalamus region of the brain that produce hypocretin peptides essential for regulating the human sleep-wake cycle (2, 3). The aim of this case report is to present and emphasize the importance of BIS monitor use in a narcoleptic patient undergoing surgery under general anaesthesia.

### CASE REPORT

A 30 year-old woman having narcolepsy diagnosis since the age of 17 requested bilateral breast reduction under general anaesthesia. She has not been taking any medication for the last 7 years. There was no family history for narcolepsy. Her medical history was unremarkable except sensitivity to wheat. The patient had uneventful caesarean section under epidural anaesthesia about 2 years ago.

Her physical examination was unremarkable. We avoided sedative premedication. On admission to the operating theatre, her arterial blood pressure was 121/76 mmHg, heart rate was 68 beat min<sup>-1</sup>, peripheral oxygen saturation was 98% while

breathing room air and the recorded BIS value was 96. Anaesthesia was induced with intravenous (iv) 1 mg kg<sup>-1</sup> of lidocaine and 2 mg kg<sup>-1</sup> of propofol and 0.6 mg kg<sup>-1</sup> of iv rocuronium was used to facilitate tracheal intubation. Ventilation was maintained using a 50% air-oxygen mixture with a fresh gas flow rate of 4 L min<sup>-1</sup>. Anaesthesia was maintained with an iv propofol infusion starting from 8 mg kg<sup>-1</sup> h<sup>-1</sup> which was then reduced incrementally to keep BIS between 40 to 60 and remifentanyl 0.15 µg kg<sup>-1</sup> min<sup>-1</sup> and both drugs were infused until the last surgical stitch. BIS value remained mostly between 40 to 60 except two points indicating 65 (Fig. 1). Muscle relaxation was maintained with 0.15 mg kg<sup>-1</sup> of rocuronium when necessary. The duration of operation was 60 minutes. 1100 grams of breast tissue was excised from each side by using inferior pedicle breast reduction technique. At the end of the operation muscle relaxation was antagonized with 0.04 mg kg<sup>-1</sup> neostigmine and 0.02 mg kg<sup>-1</sup> atropine. As soon as she was extubated, she was able to open her eyes and maintained a head lift for 5 sec. BIS value after extubation was 93. When she was transferred to the post anaesthesia care unit (PACU), she was alert and oriented. In the postoperative period the patient was interviewed to check for awareness and no recall was reported by her.

Zerrin OZKOSE, M.D., Assoc. Prof. ; Berrin GUNAYDIN, M.D., Ph.D., Assoc. Prof. ; Alper TUNGA DOGAN, M.D., Resident ; Reha YAVUZER, M.D., Assoc. Prof.

(\*) Department of Anesthesiology and Reanimation, Faculty of Medicine, Gazi University, Ankara-Turkey.

(\*\*) Department of Plastic Reconstructive and Aesthetic Surgery, Faculty of Medicine, Gazi University, Ankara, Turkey.

**Correspondence address :** Berrin Gunaydin, Department of Anesthesiology and Reanimation, Faculty of Medicine, Gazi University, Beşevler 06500, Ankara, Turkey. Tel. and fax : +90 312 225 11 52. E-mail : gunaydin@gazi.edu.tr.

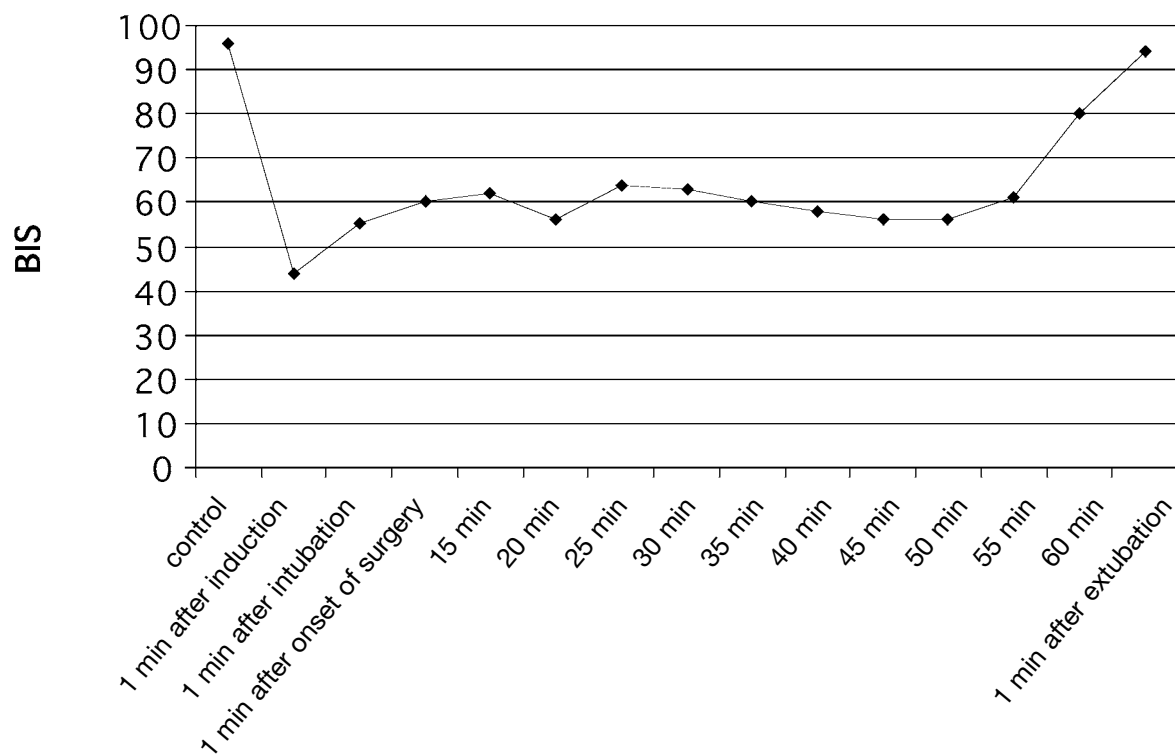


Fig. 1. — BIS values at specific time intervals throughout the procedure

She received 20 mg intravenous tenoxicam for postoperative pain relief and was transferred to the ward 40 min after extubation. Her postoperative period was uneventful without any complications or healing problems and she returned to her daily activities on the 3<sup>rd</sup> postoperative day.

## DISCUSSION

No information is available regarding the use of BIS monitor during the anaesthesia of narcoleptic patients. Delayed emergence from anaesthesia of a narcoleptic patient who went through several surgical procedures before her diagnosis was presented in one of the case reports (2). That patient awoke in the PACU and emergence times varied between 8 to 10 hours following all her previous operations. After narcolepsy diagnosis, she did wake up 4 hours after leaving the PACU following excision of a thigh mass under general anaesthesia (4). MESA *et al.* (4) reported that they used thiopental, gallamine and succinylcholine for the induction of anaesthesia followed by isoflurane in nitrous oxide for the maintenance of anaesthesia in a diagnosed narcoleptic patient scheduled to undergo coronary artery bypass grafting surgery. They reported that the patient had been extubated 6 hours after surgery in the intensive care unit. In the other case report

anaesthetic management of narcolepsy was performed with iv propofol, remifentanyl, and cisatracurium both for induction and maintenance (5).

Fortunately, treated narcolepsy patients are at no increased risk for postoperative complications (2). Additionally, it has been reported that continuation of medication for narcolepsy was safe, and the postoperative morbidity and mortality for these patients did not differ from that in the general population undergoing general anaesthesia with tracheal intubation in the first retrospective case series of narcoleptic patients (5).

In none of the fore mentioned case reports, monitoring of the hypnotic state was considered although prolonged emergence was anticipated. We, for the first time anesthetized a diagnosed narcoleptic patient scheduled to undergo breast reduction by monitoring BIS. We avoided premedication preoperatively. We used propofol and remifentanyl like PELAEZ *et al.* (5). In contrast to MESA *et al.* (4) the patient immediately opened her eyes as soon as she was extubated and we did not see any delay in emergence.

There are no previous reports on the use of BIS in narcoleptic patients. Since BIS is mainly validated as a monitor of the hypnotic component of anaesthesia of ASA I or II patients, it is somehow controversial to consider BIS as a useful tool to

achieve sufficient information in the present case report because of the possibility of the marked EEG changes during an attack of narcoleptic patients (6). However, the present subject was not symptomatic and did not have any attack history for the last 5 years.

In conclusion, central nerve system disease like narcolepsy which has a known effect on EEG might seem to limit the use of BIS. Therefore further studies are required showing potential differences in EEG changes between narcoleptic and a healthy patient. However, we might suggest that it is reasonable to monitor hypnotic state by BIS to provide an objective measure of the degree of hypnosis and early postoperative recovery since these are the principal problems in narcoleptic patients scheduled to undergo surgery under general anaesthesia.

## References

1. American Sleep Disorders Association. The international classification of sleep disorders, revised: diagnostic and coding manual. Rochester (Minn): American Sleep Disorders Association; 1997.
2. Burrow B., Burkle C., Warner D. O., Chini E. N., *Post-operative outcome of patients with narcolepsy. A retrospective analysis*, J. CLIN. ANESTH., **17**, 21-5, 2005.
3. Ebrahim I. O., Sharief M. K., de Lacy S., Semra Y. K., Howard R. S., Kopelman M. D., Williams A. J., *Hypocretin (orexin) deficiency in narcolepsy and primary hypersomnia*, J. NEUROL. NEUROSURG. PSYCHIATRY, **74**, 127-30, 2003.
4. Mesa A., Diaz A. P., *Frosth M. Narcolepsy and anesthesia*, ANESTHESIOLOGY, **92**, 1194-6, 2000.
5. Pelaez R., Hortal F. J., Bastida E., Barrio J. M., Riesgo M. J., *Narcolepsy and cardiac surgery: Can anesthesia with propofol and remifentanyl be safe?*, J. CARDIOTHORAC. VASC. ANESTH., **18**, 201-3, 2004.
6. Dyken M. E., Wenger E. J., Yamada T., *REM alpha rhythm: diagnostic for narcolepsy?*, J. CLIN. NEUROPHYSIOL., **23**: 254-7, 2006.