

## Severe stridor following the repair of H-type tracheoesophageal fistula in an 11 month infant

Y. K. BATRA, S. RAJEEV and K. L. N. RAO

**Abstract :** Congenital tracheoesophageal fistula without esophageal atresia is commonly known as "H" type and this presents with a different clinical spectrum owing to the presence of a large and patent esophagus. There may be a time lag extending up-to 50 years between first presentation and confirmation of the diagnosis owing to the rarity of the condition, its nonspecific symptomatology, and limitations in its demonstration by contrast radiology and endoscopy. Respiratory sequelae are common following repair and may persist during the rest of life. We present here, the case of an 11 month old child who presented for a definitive repair of H-type tracheoesophageal fistula, diagnosed at the age of 9 months. Following an uneventful intraoperative course the child developed severe stridor in the postanesthesia care unit (PACU) 30 min after arrival necessitating endotracheal intubation. The further course of the child in the hospital, probable reasons for this unusual complication and its management are discussed.

**Key words :** H-type ; tracheoesophageal fistula ; stridor ; postoperative.

### INTRODUCTION

Postoperative stridor occurs in up-to 2% of all pediatric patients. There are many causes that increase the risk of postintubation stridor such as traumatic intubation, airway endoscopy, laryngo- or tracheomalacia, subglottic edema, laryngeal nerve palsy and a past history of stridor. This complication may at times be severe enough to require reintubation (1). Respiratory complications are common in patients with head and neck surgery, particularly following repaired esophageal atresia/tracheoesophageal fistula (EA/TEF) (2). Although frequent spells of gurgling and stridor may occur after the repair of EA with distal TEF (commonest variety of EA/TEF) (3), to the best of our knowledge, the occurrence of severe stridor following the repair of H type TEF has never been reported before. Following repair, patients with TEF without EA (H type fistula) can present with complications like recurrent laryngeal nerve palsy, tracheomalacia, aspiration, pneumothorax, pneu-

monia, tracheal obstruction (4). As anesthesiologists and pediatric surgeons are frequently involved with stridorous neonates and infants, timely management is critical to avoid fatal airway obstruction (3).

### CASE REPORT

An 11-month male child, weighing 8 kg (ht 78.5 cm), presented with recurrent episodes of pneumonia and vomiting associated with regurgitation of food since birth. Examination revealed a nontoxic child with rhonchi on auscultation. Abdominal examination revealed hepatosplenomegaly. The child had a deformed left ear. Chest radiograph revealed diffuse interstitial markings in upper and lower zone bilaterally with no cardiomegaly and a large stomach bubble. Echocardiography and ultrasonography of the abdomen were unremarkable. Past medical history revealed that the child was born to a gravida-4, para-4 mother with no history of polyhydramnios or birth asphyxia (birth weight-3kg). On first feed, the child had developed vomiting and respiratory distress in the form of wheezing and chest recessions. Subsequently, the baby was hospitalized in the intensive care unit till day 22 of life. On day 25 the child was rehospitalised for feeding difficulties, respiratory distress and abdominal distension. Feeding difficulty was associated with difficulty in swallowing, nasal regurgitation of feeds, marked rattling noise and choking episodes. Laryngoscopy revealed

Yatindra Kumar BATRA, M.D., M.N.A.M.S., F.A.M.S.;  
Subramanyam RAJEEV, M.D., D.N.B., M.N.A.M.S. ;  
Katragadda L. N. RAO, M.S., M.Ch., F.A.M.S.

Departments of Anaesthesia & Intensive Care, and Paediatric surgery, Postgraduate Institute of Medical Education and Research, Chandigarh-160012 (India).

**Address for correspondence :** S. Rajeev, Senior Resident, Anaesthesia and Intensive Care unit, Postgraduate Institute of Medical Education and Research, Chandigarh-160012, India. E-mail : docrajeevs@gmail.com

intact mobile vocal cords with no evidence of laryngomalacia. Gastroesophageal reflux study done by acquiring serial images over 3 min by administering 18.5 MBq of  $^{99m}\text{Tc}$  sulfur colloid mixture in milk via a nasogastric tube showed evidence of reflux of radiotracer into esophagus suggestive of gastroesophageal reflux disease. Gastrograffin study was normal. Colonoscopy and rectal biopsy was performed to rule out Hirschsprung's disease. High resolution computed tomography revealed left meatal and external auditory canal atresia. Audiometry was indicative of minimal hearing loss. Feeding difficulty improved with the child's growth, but abdominal distension was persistent. Hence, a panendoscopy was planned. Anesthesia was provided with fentanyl, oxygen, nitrous oxide, sevoflurane and airway secured with a 4 mm ID endotracheal tube (ETT) using atracurium. Flexible bronchoscopy did not reveal an obvious fistula. Esophagoscopy revealed a fistula and a guidewire was passed which could be visualized with a repeat bronchoscopy inside the trachea about 2-3 cm above carina. Contrast esophagogram was performed by placing a 5Fr infant feeding tube and injecting iohexol, while the tube was gradually withdrawn into the neck. This revealed the presence of a fistulous communication between trachea and esophagus at the cervicodorsal junction (Fig. 1). A definitive corrective surgery was planned. A preoperative chest radiograph was unremarkable. Anesthesia was induced with oxygen, nitrous oxide, sevoflurane and the airway was secured with 4 mm ID ETT using atracurium. Maintenance was provided with fentanyl, oxygen, nitrous oxide, isoflurane and atracurium top-ups. Mobilization of the esophagus, tracheoesophageal fistula and ligation/transsection of fistula was performed through a right sided neck incision. Tracheomalacia was ruled out by careful palpation of the trachea by the surgeon. Surgery lasted for 80 min after which muscle paralysis was reversed. The child was extubated. An awake laryngoscopy confirmed the normal mobility of vocal cords confirming preservation of both recurrent laryngeal nerves and the child shifted to the post anesthesia care unit (PACU) without any event. After about 30 min, the child started to have severe chest retractions and noisy breathing. Examination of the chest revealed bilateral crepitations, stridor, and suprasternal retractions. Arterial blood gas analysis revealed uncompensated metabolic (with  $\text{PaO}_2$  of 64.5 mmHg) acidosis. The child was nebulized with racemic epinephrine. Meanwhile, oxygen desaturation to 90% was noticed, when the child was mask ventilated. The

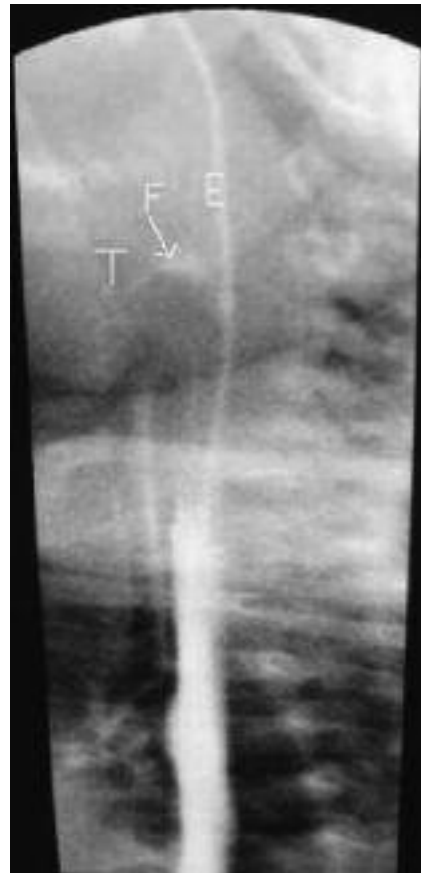

Fig. 1. — An H type tracheoesophageal fistula (F) outlined by contrast during an esophagogram. A small amount of contrast has entered the trachea (T). Esophagus (E).

airway was secured following the administration of 30 mg thiopentone and 10 mg of suxamethonium. As moderate resistance was encountered while intubating with a 4 mm ID ETT, the use of a 3.5 mm ID ETT was necessary. Suctioning of the ETT was done and the child was stabilized. Subsequently dexamethasone was given and sedation was provided with midazolam. Chest radiograph revealed evidence of aspiration (Fig. 2). The child was given a trial of extubation on POD 2, but had to be reintubated due to recurrent stridor. At this time a flexible bronchoscopic examination was performed with topical anesthesia using 4% lignocaine, and sedation with fentanyl and midazolam. It revealed significant edema below the glottis. Trauma of the airway either resulting from intubation and tube manipulation causes stridor and the presence of subglottic edema is usual in such cases. The use of appropriately sized endotracheal tubes and assurance of a leak below 30 cm  $\text{H}_2\text{O}$  pressure decreases the risk of airway trauma. A repeat extubation trial on day also 4 failed. Subsequently the child developed pneumonia and was treated with

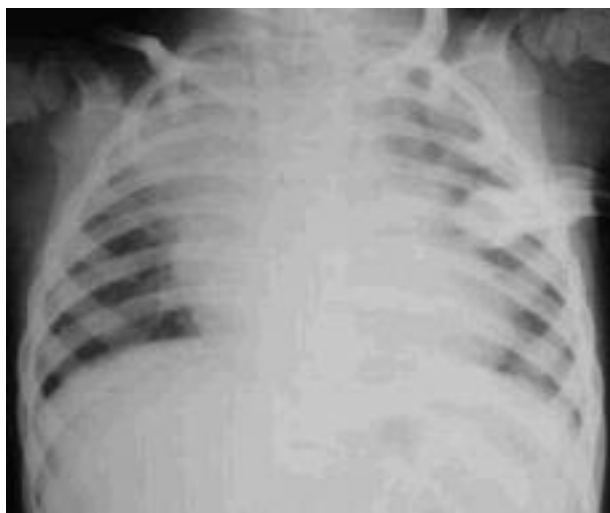

Fig. 2. — Chest radiograph revealing areas of consolidation in the right upper lobe consistent with aspiration.

broad spectrum antibiotics. After the child's condition gradually improved, he was successfully extubated on POD 10 and discharged home.

#### DISCUSSION

H-type tracheoesophageal fistula refers to a fistula between the posterior wall of the trachea and a more caudal position on the anterior wall of the esophagus (5). These fistulas can occur anywhere from the cricoid cartilage to the carina. H-type TEF constitutes 4 to 6% of the tracheal and esophageal anomalies. These are also known as N-type fistulas as they extend in an oblique course like the letter N (6). H-type TEF can be subtle in presentation and presents a diagnostic challenge. Symptoms typically start at birth often with the first feed due to the passage of air or liquid through the fistula causing choking and cyanotic attacks (4). Despite its congenital nature, diagnosis and surgical correction up to the age of 50 years of age has been reported. In one series, the mean age at diagnosis was 8 months (6). Our patient was subjected to various diagnostic tests and an esophagogram performed with iohexol, at the age of 9 months suggested the presence of an H-type TEF.

Although initial flexible bronchoscopy did not reveal the presence of a fistula, TEF was diagnosed by esophagoscopy. Small flexible bronchoscopes seem to be the least successful in detecting this anomaly (3). The various mechanisms proposed for this diagnostic delay include the presence of an occlusive valve like a mucosal flap, which may

close during swallowing due to the obliquity of the tract and swallowing-induced spasm of the muscular layer occluding the lumen (6). The symptomatology produced differs from other types of TEF due to the presence of a large and patent esophagus. H-type TEF may rarely be associated with the presence of congenital esophageal stenosis (7).

Various methods that have been developed to prove the presence of a suspected H type TEF include contrast esophagogram, and/or cine-esophagogram and bronchoscopy. Our case was diagnosed by contrast esophagogram as the fistulous opening was not seen during initial bronchoscopy. Definitive surgical therapy is performed either through a cervical or a thoracic approach depending on the level of the fistula (6). Cervical approach was used in our patient as the fistula was at the level of cervico-dorsal junction. Our patient's postoperative course was initially complicated by severe stridor about 30 min after transfer to the PACU following uneventful surgery and this was relieved with endotracheal intubation. Chest radiograph revealed areas of consolidation in the right upper lobe consistent with aspiration.

Respiratory symptoms are common in patients with repaired EA/TEF. In various studies respiratory complications have been due to recurrent pneumonia, aspiration, choking, gagging or cyanosis with feeds, GERD, tracheomalacia, recurrent TEF and esophageal stricture, while many patients had multiple causes. Respiratory and GI sequelae in patients with a history of EA/TEF result from a complex interplay of numerous potential complications, and some complications can exacerbate others (8). The postoperative complications following the repair of TEF, which may lead to stridor include intraoperative damage of recurrent laryngeal nerve, edema due to surgical manipulation, tracheomalacia, or tracheal obstruction. Airway hyper-reactivity has also been suggested as a possible explanation for the stridor in these procedures and this selected population but little information is available. In addition, the other complications include pneumothorax and postoperative aspiration (4, 9). Recurrent laryngeal nerves (unilateral or bilateral) are vulnerable to damage during operative dissection as they lie in the groove between the trachea and the esophagus, and are closely related to the fistula. This has anesthetic implications in that inspection of the vocal cords has to be carried out at the end of surgery (10). This possibility was ruled out in our case as vocal cords were confirmed mobile, and a repeat inspection in the PACU also revealed mobile cords.

Tracheomalacia causes either a generalized or localized weakness of the trachea and allows the anterior and posterior wall to come together causing stridor when severe (11). In addition, the flaccid trachea gets easily compressed between the aorta anteriorly and the esophagus posteriorly (12). SLANY *et al.* (13) in a study on 59 children, who underwent a successful repair of TEF, demonstrated that 91% of these patients present with some degree of tracheal collapse. The diagnosis of tracheomalacia is difficult in these children as they may have associated neurological, cardiac or esophageal disorders producing symptoms similar to tracheomalacia (9). Bronchoscopic examination was performed to rule out the presence of tracheomalacia (14). Although no evidence of tracheomalacia was found, significant edema below the level of glottis was present, which was the cause for stridor. This could have resulted from operative manipulation because of the proximity of the fistula to the subglottic area. Due to this proximity, the child may also have had aspiration in the immediate postoperative period which was evident on the chest radiograph.

Laryngeal edema due to surgical manipulation is known to produce stridor in the postoperative period. Epinephrine nebulization and dexamethasone were administered and since there was no response, a plan to intubate was made. Hence we presumed laryngeal edema as the main reason for the severe stridor. It is important to rule out the presence tracheomalacia in young children with pronounced wheezing associated with EA/TEF, as bronchodilators may worsen airflow, by relaxing tracheal smooth-muscle tone necessary for maintaining airway patency. These children may benefit from the administration of smooth muscle stimulants, such as bethanachol and discontinuation of bronchodilators (15).

The immature airways of children and neonates are more compliant than those of adults and are particularly susceptible to stridor and, therefore, are more prone to collapse. Furthermore, the diameter of a child's airway is so small that only a slight reduction in diameter causes a considerable reduction in cross sectional area. Stridor can be divided into an acute or subacute/chronic type of

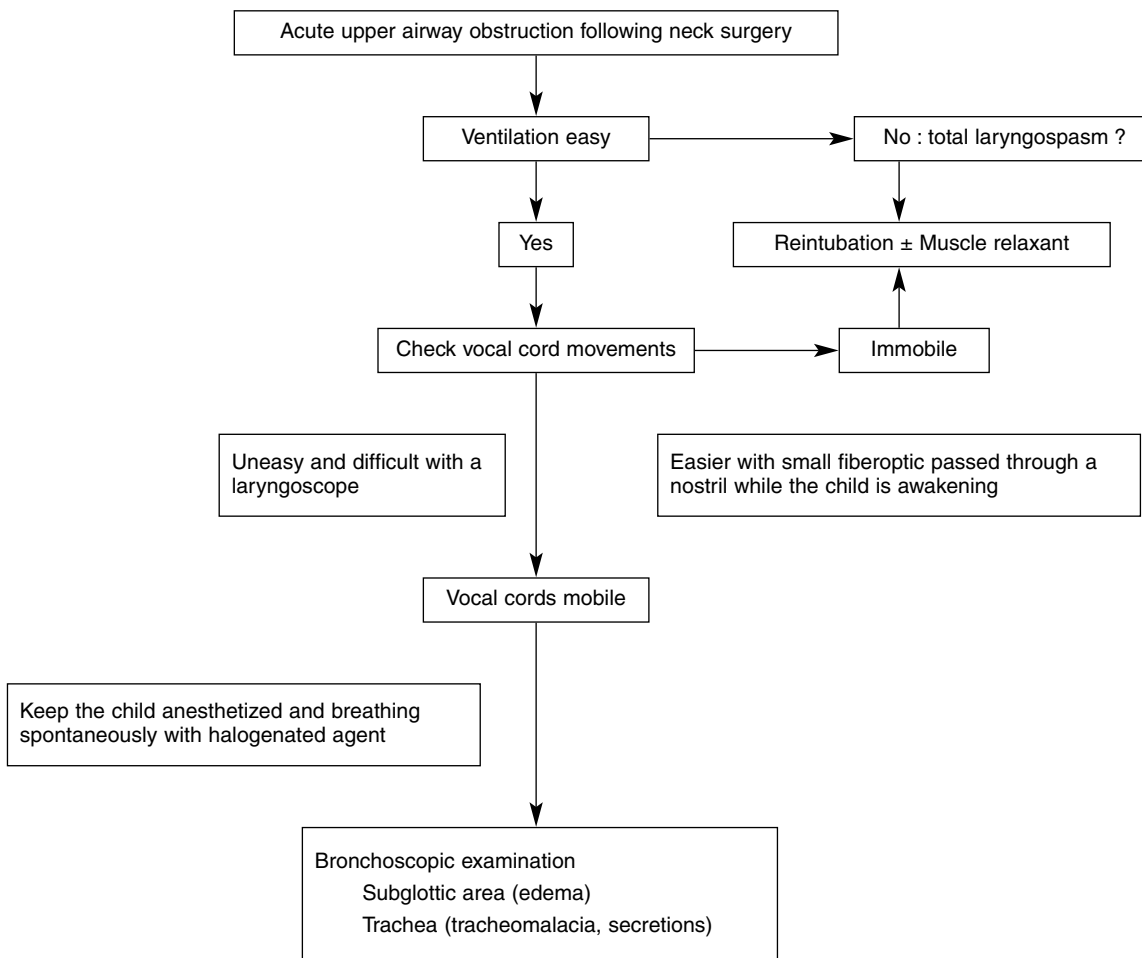


Fig. 3. — Decision Making Process

presentation. Acute stridor develops over hours and is a critical condition requiring immediate assessment and treatment (16). When confronted with postoperative stridor, in the acute situation (Fig. 3), assessment, and active resuscitation will often proceed in parallel to stabilizing the airway as expeditiously as possible. With an obstruction to airflow but normal alveolar function, increasing the concentration of inspired oxygen will reduce the ventilatory requirement to maintain adequate oxygen saturation. Nebulization with epinephrine (5 mL of 1:1000) or racemic epinephrine (0.5 mL) should be considered for children who have moderate or severe respiratory distress. Nebulization with budesonide or iv dexamethasone may reduce stridor caused by airway edema. Severe cases require reintubation and prolonged ventilation (17). Our case showed that severe stridor can follow the repair of TEF even without EA. Adequate preparation for managing this catastrophic complication in patients undergoing repair of H type TEF is imperative. Preoperative assessment of common complications is important, as success rates are reduced when other conditions such as gastro-esophageal reflux disease are present (18). Preoperative laryngo-tracheoscopy should be recommended because it allows the preoperative diagnosis of laryngo- or tracheomalacia, the exact location of the fistula, the diagnosis of any associated anomaly such as a tracheal bronchus. Preparation of these patients includes cessation of feeding, optimization of respiratory status, starting up appropriate antibiotics, observation and monitoring of vital signs. Careful inspection of the vocal cords is imperative in the immediate postoperative period to rule out recurrent laryngeal nerve palsy.

## References

1. Wetzel R. C., *Anesthesia and perioperative care*. In : Behrman R. C., Kleigman R. M., Jenson H. B., eds. Nelson textbook of Pediatrics. 17th ed. Saunders Pennsylvania, 342-357, 2004.
2. Delius R. E., Wheatley M. J., Coran A. G., *Etiology and management of respiratory complications after repair of esophageal atresia with tracheoesophageal fistula*, SURGERY, **112**, 527-532, 1992.
3. Holzki J., Laschat M., Stratmann C., *Stridor in the neonate and infant. Implications for the paediatric anaesthetist. Prospective description of 155 patients with congenital and acquired stridor in early infancy*, PAEDIATRIC ANAESTHESIA, **8**, 221-227, 1998.
4. Beasley S. W., *Tracheo-oesophageal fistula*. In : Atwell J. D., ed. Paediatric surgery Arnold NY, pp 187-196, 1998.
5. Benjamin B., Pham T., *Diagnosis of H-type tracheoesophageal fistula*, JOURNAL OF PEDIATRIC SURGERY, **26**, 667-671, 1991.
6. Karnak I., Senocak M. E., Hicsonmez A., Büyükpamukçu N., *The diagnosis and treatment of H-type tracheoesophageal fistula*, JOURNAL OF PEDIATRIC SURGERY, **32**, 1670-1674, 1997.
7. Homnick D. N., *H-type tracheoesophageal fistula and congenital esophageal stenosis*, CHEST, **103**, 308-309, 1993.
8. Kovesi T., Rubin S., *Long-term complications of congenital esophageal atresia and/or tracheoesophageal fistula*, CHEST, **126**, 915-925, 2004.
9. Filler R. M., Messineo A., Vinograd I., *Severe tracheomalacia associated with esophageal atresia : results of surgical treatment*, JOURNAL OF PEDIATRIC SURGERY, **27**, 1136-1140, 1992.
10. Beasley S. W., *Esophageal atresia and tracheoesophageal fistula*. In : Oldham K. T., Colombani P. M., Foglia R. P., et al., eds. Principles and practice of pediatric surgery. LWW Philadelphia, pp 1039-1052, 2005.
11. Benjamin B., *Tracheomalacia in infants and children*, THE ANNALS OF OTOLARYNGOLOGY, RHINOLOGY AND LARYNGOLOGY, **93**, 438-442, 1984.
12. Schwartz M. Z., Filler R. M., *Tracheal compression as a cause of apnea following repair of tracheoesophageal fistula : treatment by aortopexy*, JOURNAL OF PEDIATRIC SURGERY, **15**, 842-848, 1980.
13. Slany E., Holzki J., Holschneider A. M., Gharib M., Hügel W., Mennicken U., *Tracheal instability in tracheoesophageal abnormalities*, ZEITSCHRIFT FÜR KINDERCHIRURGIE, **45**, 78-85, 1990.
14. Austin J., Ali T., *Tracheomalacia and bronchomalacia in children : pathophysiology, assessment, treatment, and anaesthesia management*, PAEDIATRIC ANAESTHESIA, **13**, 3-11, 2003.
15. Panitch H. B., Keklikian E. N., Motley R. A., Wolfson M. R., Schidlow D. V., *Effect of altering smooth muscle tone on maximal expiratory flows in patients with tracheomalacia*, PEDIATRIC PULMONOLOGY, **9**, 170-176, 1990.
16. Goodman T. R., McHugh K., *The role of radiology in the evaluation of stridor*, ARCHIVES OF DISEASE IN CHILDHOOD, **81**, 456-459, 1999.
17. Albert D., Leighton S., *Managing the stridulous child*. In : Cummings C. W., Harker L. A., Robbins T. K., Haughey B. H., Thomas R. J., eds. Cummings : Otolaryngology : Head & Neck Surgery, 4th ed., Mosby, 4241-4265, 2005.
18. Corbally M. T., Spitz L., Kiely E., Brereton R. J., Drake D. P., *Aortopexy for tracheomalacia in oesophageal anomalies*, EUROPEAN JOURNAL OF PEDIATRIC SURGERY, **3**, 264-266, 1993.