

Local anaesthetic use for the iliac crest-donor site : pharmacokinetic and pharmacodynamic evaluations

J. P. ESTEBE (*, **, ***), P. LE CORRE (**), A. LE NAOURES (*, ***), C. ELIAT (*, ***), F. CHEVANNE (**), J. L. HUSSON (***) and C. ECOFFEY (*)

Abstract : During orthopaedic surgery of the limb, we performed a prospective, double blind controlled study on three parallel groups in 30 patients to evaluate the pharmacokinetic and pharmacodynamic effect of infiltration of the iliac crest bone graft harvest site with 20 ml of bupivacaine (100 mg), ropivacaine (150 mg) or saline as control group (n = 10 in each group). Then, in a sheep model of iliac crest infiltration, we compared the pharmacokinetics of single administration of plain bupivacaine (100 mg) and bupivacaine (500 mg)-loaded microspheres.

In the clinical control group, pain from the iliac crest was worse than pain from the primary surgical site. Pain from the iliac crest was significantly reduced during the first 12 postoperative hours in local anaesthetic groups compared to the control group. However, during this period, pain from the primary surgical site was increased compared to the control group. Finally, there was no difference between the three groups in the average intake of PCA morphine. There was no significant pharmacokinetic and pharmacodynamic difference between plain bupivacaine and ropivacaine. The maximal plasma concentration (C_{max}) of ropivacaine and bupivacaine were 964 (282) ng.ml⁻¹ and 638 (366) ng.ml⁻¹, respectively. In the sheep model, it was clearly shown that the release of bupivacaine from microspheres was controlled and prolonged despite the largest dose of bupivacaine used (500 mg ; n = 4).

Wound infiltration of iliac crest harvest site with local anaesthetic is an easy technique for postoperative analgesia. However, this effect lasts only 12 hours without reducing the morphine consumption due to an increase of pain from the primary surgical site. The local anaesthetic infiltration produced a significant peak of plasma level, which could be dangerous if another infiltration or regional anaesthetic technique was associated with it. Experimentally, as a drug delivery system, the use of local anaesthetic-loaded microspheres could be an interesting alternative.

Key words : Local anaesthetics : bupivacaine, ropivacaine, bupivacaine-loaded microspheres ; wound infiltration : iliac crest, bone graft harvest ; analgesia : postoperative pain.

INTRODUCTION

Autologous bone grafts from the ilium are frequently harvested for purposes of bone fusion in patients undergoing limb stabilization surgery. However, the pain from the donor site (secondary surgical site) is often more severe than from the limb incision (primary surgical site) (1-3). Wound infiltration with local anaesthetic seems to be effective but just for a short period (3, 4). In order to prolong this analgesic effect, it was proposed to perfuse local anaesthetics through a catheter (4). No data are available concerning the pharmacokinetics and pharmacodynamic effects of local anaesthetics from a wound administration in an iliac crest bone graft. We performed a prospective, double blind controlled study on three parallel groups to evaluate the pharmacokinetics and pharmacodynamic effect of a single administration of two local anaesthetics (bupivacaine and ropivacaine). Then, in a sheep model of iliac crest infiltration, we compared the pharmacokinetic effect of a single administration of plain bupivacaine and bupivacaine-loaded microspheres as a drug delivery system used for the controlled release and prolonged effect of local anaesthetics.

J. P. ESTEBE, M.D., Ph.D. ; P. LE CORRE, Pharm.D., Ph.D. ; A. LE NAOURES, M.D. ; C. ELIAT, M.D., F. CHEVANNE, B.Sc., J.L. HUSSON, M.D. ; C. ECOFFEY, M.D.

(*) Service d'Anesthésie Réanimation Chirurgicale 2.

(**) Laboratoire Optimisation biopharmaceutique par modulation des passages transmembranaires.

(***) Service d'Orthopédie Traumatologie A.

University of Rennes 1, Rennes, France.

Correspondence address : Dr. J.-P. Estebe, Service d'Anesthésie Réanimation 2, CHRU de Rennes, Hôpital Hôtel Dieu, 2 rue de l'Hôtel Dieu, 35000 Rennes, France.

Tel. : 33 2 99 87 30 09. Fax : 33 2 99 87 34 13.

E-mail : jean-pierre.estebe@chu-rennes.fr

MATERIAL AND METHODS

After the approval of the Ethics Committee and written informed consent, 30 adult ASA physical status I-II patients were prospectively included for limb orthopaedic surgery utilizing autogenous bone harvested from the ilium. All were found to be in normal health by medical history and physical examination and were within 10% of ideal body weight.

Standardized anaesthesia was induced using intravenous injection of 0.5 microgram.kg⁻¹ of sufentanil, 4 microgram/kg of thiopental and 0.5 microgram/kg rocuronium bromide was used to allow tracheal intubation. Patients were ventilated mechanically using 50/50 oxygen / nitrous oxide in a semi-closed system and kept normocarbic (end-tidal CO₂ = 4.0-4.7 kPa). Anaesthesia was maintained using isoflurane (1 to 1.5 minimum alveolar concentration) and additional intravenous injections of 0.1 to 0.5 microgram.kg⁻¹ of sufentanil each hour or in case of arterial pressure or heart rate increase of at least 20% above initial values until the end of surgery. Thirty minutes before the end of surgery, patients received a slow infusion of 2 g of propacetamol and a bolus of 100 mg of ketoprofen intravenously.

After the surgical closure, the wound at the anterior iliac crest was randomly infiltrated by the surgeon with 20 ml of ropivacaine 0.75% (Naropeine, Astra-Zeneca, Reuil-Malmaison, France) (150 mg), with 20 ml of plain bupivacaine 0.5% (Marcaine, Astra-Zeneca, Reuil-Malmaison, France) (100 mg) or with 20 ml of saline (Control Group); n = 10 for each group. The wound blood draining off was started 15 minutes after wound infiltration.

The main endpoint of our pilot study was a pharmacodynamic evaluation. After surgery, the pain was evaluated using the Visual Analog Scale (VAS 0-100 mm; time zero = time at the first evaluation before analgesic treatment) and was recorded for 48 hours from the two operative sites (harvest site = secondary surgical site and limb site = primary surgical site) by the nurse of the postoperative care. This nurse had no prior knowledge of the experiment and the associated protocol. Secondary endpoint was post-operative cumulated morphine consumption through Patient Controlled-Analgesia (PCA) during the 24 hours following extubation. In postoperative care unit, intravenous (iv) morphine titration (3 mg of morphine each 7 min) was performed to reduce patient's pain below 40 mm on a 0-100 mm VAS. Then, the patient used PCA (i.e.

1 mg of morphine with 7 min refractory period, and a maximum dose of 20 mg per period of 4 hours; time zero = time at the end of morphine titration). Post-operative analgesia also included, if not contra-indicated, 8 g of propacetamol and 200 mg of ketoprofen daily.

For a pharmacokinetic evaluation blood samples were drawn from a venous catheter immediately before and after injection of local anaesthetics according to a standard time-schedule protocol (0 : before injection; 1, 5, 15, 30, 45 minutes and 1, 2, 3, 4, 12 and 24 hours after injection). The measurement of plasma bupivacaine and ropivacaine concentration was performed by high-performance liquid chromatography (5). The limit of detection was 2 ng.m⁻¹; the within-day and the between-day reproducibilities were 2.1% and 5.6%, for bupivacaine and 0.9 ng.ml⁻¹, 1.9%, and 4.1% for ropivacaine respectively.

Statistical significance was defined as $P < 0.05$. Patients with allergic history of local anaesthetics were excluded. In a previous study (6), we have shown that post-operative VAS was significantly reduced when we infiltrated the iliac bone craft harvest site with 20 ml of 0.75% ropivacaine compare to a group without infiltration (n = 15 for each group). Based on these results, we calculated a sample size that would permit a type I error of $\alpha = 0.05$ with a type II error of $\beta = 0.05$ and power of 95%. Enrolment of 10 patients in each group was required. Patients were not included in the study when local anaesthetics were used for another indication. Results are presented as mean (SD). Data were analyzed using the analysis of variance followed by the unpaired Student's *t*-test with Bonferroni correction for the comparison of continuous variables and chi-square test (or Fisher's exact test when appropriate) was used for the comparison of categorical variables.

As an alternative to the use of a catheter to prolong the effect of local anaesthetics, we evaluated in a pharmacokinetic study another drug delivery system to prolong a block. Indeed, to avoid the risk of infection due to the use of catheter (7), the use of local anaesthetics loaded microspheres in a single shot administration would be an interesting option (8). In comparison to our clinical study, and after approval of our local animal care committee, the same surgery (i.e. autogenous bone harvested from the ilium) was performed in sheep for preliminary pharmacokinetic evaluation under general anaesthesia. After surgical closure wound infiltration was performed with 20 ml of plain bupivacaine (100 mg) or with 500 mg of bupivacaine-

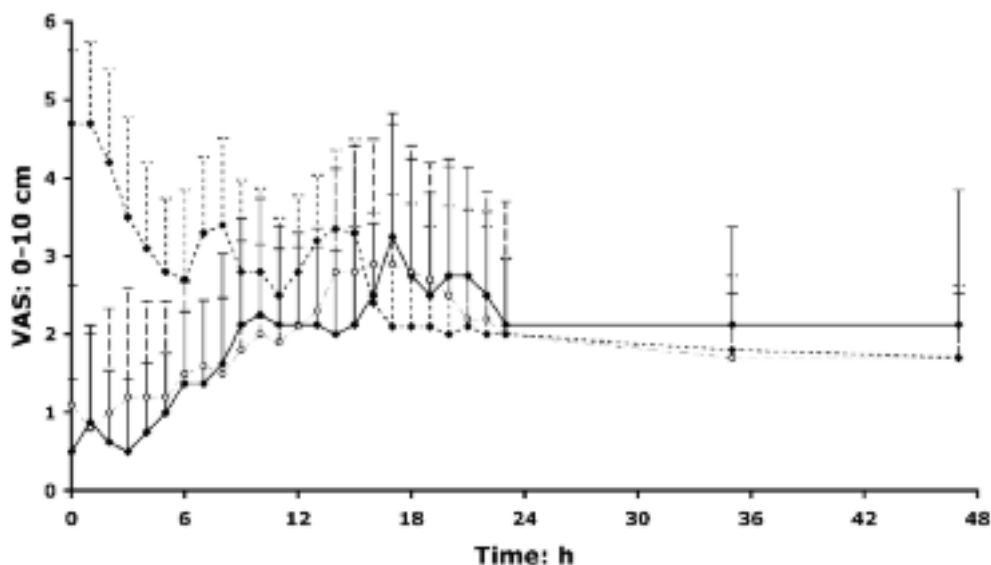


Fig. 1. — Visual Analogue Scale (VAS) values obtained from secondary surgical site (iliac crest donor site) (0-10 cm), after infiltration of the iliac crest donor site with 20 ml of bupivacaine (100 mg ; \circ and interrupted line), ropivacaine (150 mg ; \blacklozenge and continuous line), or saline (\blacklozenge and interrupted line). Data are presented as mean (SD) ($n = 10$ in each group). Time zero is at the first VAS evaluation before morphine titration.

loaded microspheres ($n = 4$ for each group). Such microspheres have been previously used as a carrier of bone growth factor for the treatment of a diaphysal non-union (9). Also a pharmacokinetic comparison was performed between plain bupivacaine and bupivacaine-loaded microspheres to allow a preclinical evaluation. Bupivacaine-loaded microspheres production was previously described (10).

RESULTS

30 patients were successively and randomly included. There was no significant difference between groups considering age, weight, sex ratio, type of surgery (lower or upper limb), per-operative sufentanil consumption, anaesthesia duration, use of propacetamol and ketoprofen, time to extubation, or time between infiltration and extubation. No adverse effect such as haematoma or infection was recorded from the iliac crest site. No adverse effects of the local anaesthetics were clinically recorded.

All patients could clearly differentiate pain at the donor site from pain at the site of limb fusion. Pain at the iliac crest measured with the VAS was the same in the ropivacaine and bupivacaine group and lower than in the control group for the first 12 hours ($P < 0.001$; Fig. 1). Conversely, pain at the operated limb measured with the VAS score was

lower between 4 to 12 hours in the control group compared to the ropivacaine and bupivacaine group (Fig. 2; $P < 0.01$). Whereas in the control group, pain from the iliac crest was significantly greater than pain from the primary surgical site; in local anaesthetics groups, pain from the primary surgical site was greater than pain from the iliac crest. After the first 12 hrs of the postoperative period there was no significant difference in the infiltrated groups compared to the control group.

There was no significant difference in the dose of morphine administered during titration or in the average intake of morphine PCA during 24 hrs (Fig. 3).

Considering the pharmacokinetic analysis the maximal plasma concentration (C_{max}) of ropivacaine and bupivacaine was $964 \pm 282 \text{ ng.ml}^{-1}$ and $638 \pm 366 \text{ ng.ml}^{-1}$ respectively with similar T_{max} ($30 \pm 10 \text{ min}$) (Fig. 4). No local anaesthetic was detected from the postoperative blood loss suction from the ilium in 2 patients for each local anaesthetic group.

The plasma levels of the sheep model are depicted in figure 5. In the bupivacaine group (100 mg of bupivacaine), the C_{max} was $187 \pm 107 \text{ ng.ml}^{-1}$ and the T_{max} was $20 \pm 15 \text{ min}$. In the bupivacaine-loaded microspheres group (500 mg of bupivacaine), the C_{max} was $96 \pm 87 \text{ ng.ml}^{-1}$ and the T_{max} was around 100 min.

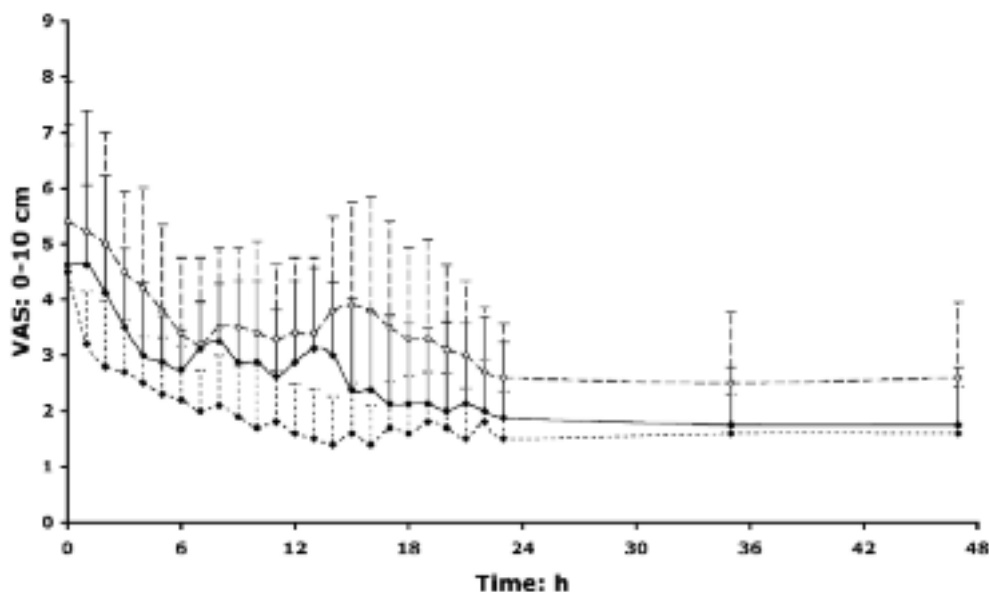


Fig. 2. — Visual Analogue Scale (VAS) values obtained from primary surgical site (surgical limb) (0-10 cm), after infiltration of the iliac crest donor site with 20 ml of bupivacaine (100 mg ; \circ and interrupted line), ropivacaine (150 mg ; \blacklozenge and continuous line), or saline (\blacklozenge and interrupted line). Data are presented as mean (SD) ($n = 10$ in each group). Time zero is the first VAS evaluation before morphine titration.

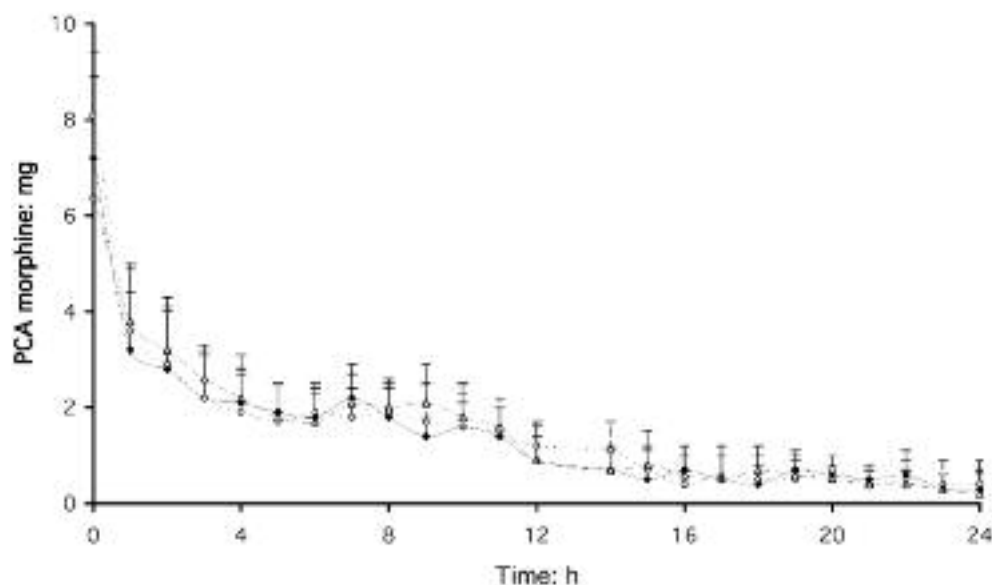


Fig. 3. — Consumption of morphine (iv titration and Patient Controlled Analgesia) (mean \pm SD) after infiltration of the iliac crest donor site. Infiltrations were performed with 20 ml of bupivacaine (100 mg, \circ and discontinuous line), ropivacaine (150 mg ; \triangle and interrupted line), or saline (\blacklozenge and continuous line). All data are presented as mean (SD) ($n = 10$ in each group). Time zero is at the end of the morphine titration.

DISCUSSION

This is the first study in which pharmacodynamic and pharmacokinetic evaluations were performed simultaneously and this study shows a significant, although transient, effect of local infiltration of the iliac bone graft. No difference between ropivacaine and bupivacaine infiltration was observed.

In the control group, pain from the iliac crest was significantly greater than pain from the primary surgical site. Donor site pain often constitutes the most intense pain experienced by patients after limb fusion. Our clinical data are in agreement with previous studies (2, 4, 6, 11) showing that infiltration of local anaesthetic is an effective method to provide analgesia in this setting. However, as suggested in previous studies the effect of infiltration with

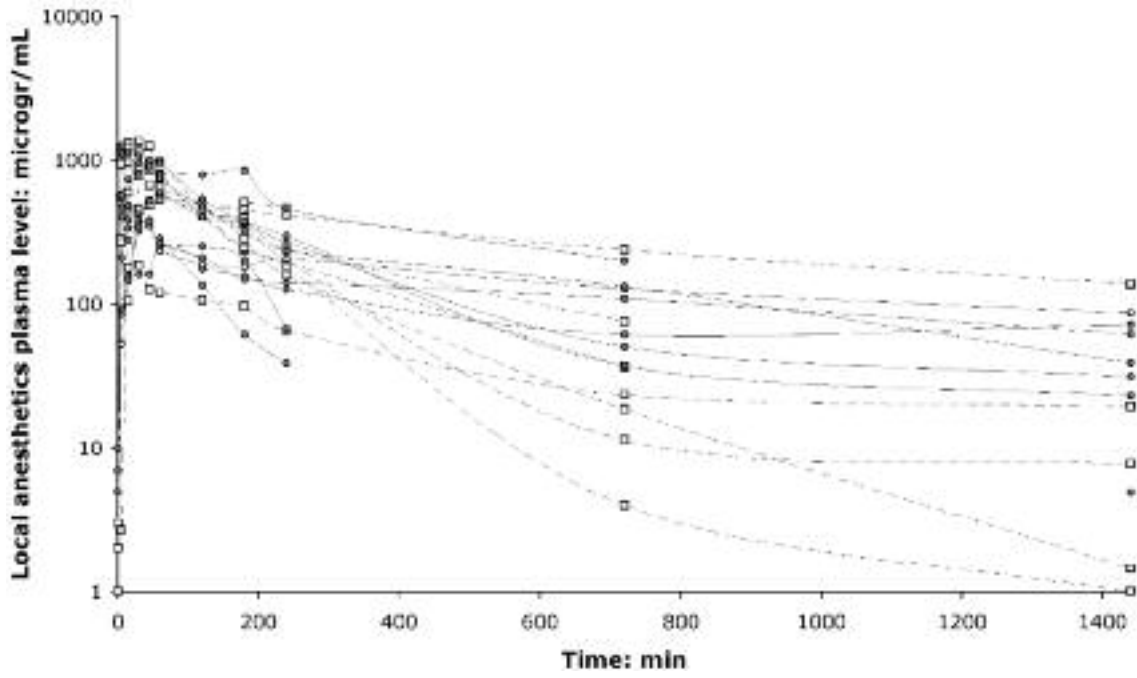


Fig. 4. — Local anaesthetic plasma concentrations after infiltration of the iliac crest donor site with 20 ml of bupivacaine (100 mg ; ● and continuous line) or ropivacaine (150 mg ; □ and interrupted line). Time zero is the time at the first blood sample just before infiltration.

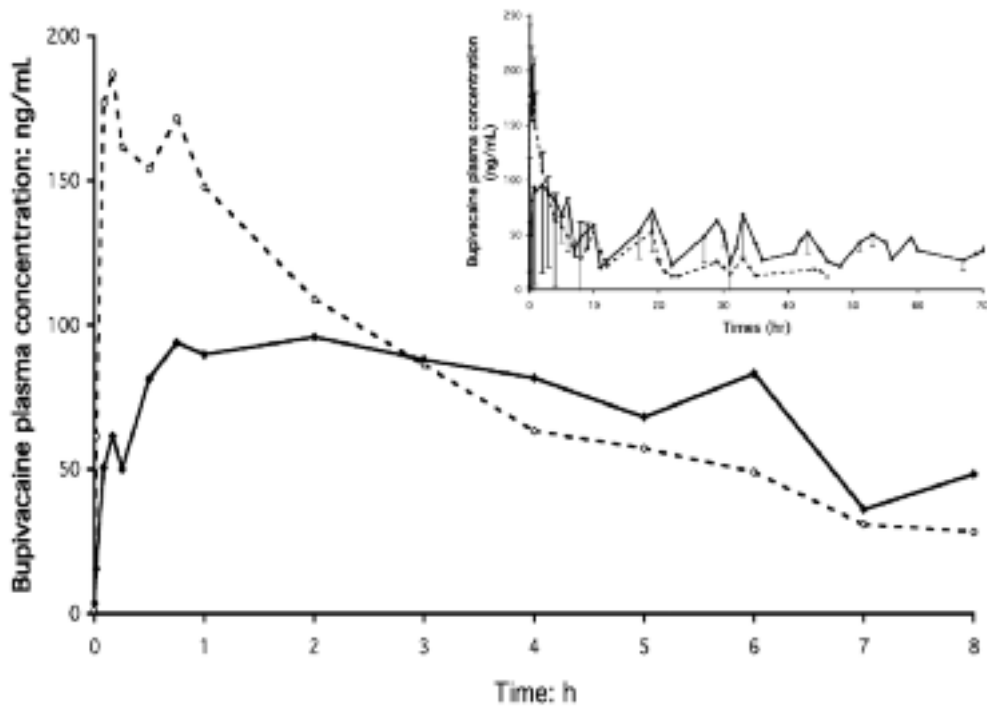


Fig. 5. — Local anaesthetic plasma concentrations after infiltration of the iliac crest of sheep performed with 20 ml of bupivacaine (100 mg ; ○ and interrupted line) or (500 mg loaded-microspheres ; ◆ and continuous line). All data are presented as mean (SD) (n = 4 in each group). Time zero is the time for the first blood sample just before infiltration.

local anaesthetics is transient (2, 4, 12). No relevant clinical difference was recorded when 100 mg of bupivacaine was compared to 150 mg of ropivacaine. Given the 1.5 fold difference in drug dosing, the peak plasma concentration was identical, suggesting a lack of difference in drug absorption from the site of administration, as also suggested by the similar T_{max} .

In our study, infiltration of the iliac crest was not sufficient to decrease the postoperative morphine intake. These results were in agreement with the similar maximal VAS scale reported (from the ilium in the saline-infiltrated group and from the primary surgical site in the infiltrated groups). A specific evaluation of pain from the primary site showed that local infiltration of the iliac crest had no effect on pain from the limb. Conversely, when the worst pain (from the iliac crest) was reduced, patient perception seemed to be orientated toward the second site of pain (i.e. primary site). These results are different than those previously reported in another investigation (4). In this study the spinal surgery incision was close to the ilium donor site and included a less active period. In our study, because the primary site was the limb, patient mobilization was more important. It is also important to notice that it was reported that pain from the anterior harvests (as in our study) was more severe than posterior iliac harvests (13).

Our study is the first to evaluate the pharmacokinetic aspects of infiltration on a large area of decorticated iliac bone crest. These results are clinically relevant because they showed a significant absorption of local anaesthetics. Particularly for two patients in each group, plasma peaks were high: 1373 and 1240 $\text{ng}\cdot\text{ml}^{-1}$ for ropivacaine and 1266 and 1141 $\text{ng}\cdot\text{ml}^{-1}$ for bupivacaine; suggesting a risk of toxicity in case of association with other regional anaesthetic techniques. The discussion about the toxic dose of local anaesthetics remains unclosed due to the lack of distinction between tissue absorption and accidental intravenous injection (14). Indeed, in limb orthopaedic surgery, the pain from the site of limb fusion could be easily blocked with regional anaesthesia. With the local anaesthetics doses used in our study, we do not recommend the association of regional anaesthesia with iliac crest infiltration. Further studies must be performed. In the aim to determine if lower doses of local anaesthetics could be used with a similar clinical effect, it would be particularly interesting to perform a dose-ranging study. It was reported that morphine infiltration is effective for the treatment

of pain from iliac crest and spine (15, 16). Another alternative solution could be to add morphine to lower local anaesthetic doses.

Prolongation of analgesia at the donor iliac crest site could be obtained with a catheter (4, 7) or by repeated injection (12) with a risk of lack of efficacy and an increased added risk of infection (17). Drug delivery systems such as bupivacaine-loaded microspheres could be an interesting tool as suggested for regional anaesthesia (8). Such implants containing bone growth factor were previously used to create an effective bone graft substitute for the treatment of diaphyseal non-union in an experimental model (9). A significant difference in C_{max} of bupivacaine following the administration of the same dose of bupivacaine (100 mg) compared to human results ($96 \pm 87 \text{ ng}\cdot\text{ml}^{-1}$ and $638 \pm 366 \text{ ng}\cdot\text{ml}^{-1}$, respectively) was observed in sheep model. The number of animal was too small ($n = 4$) to allow comparison with the human study (plasma concentrations scattering). However, this preliminary experimental study clearly shows that the release of bupivacaine from microspheres was controlled and prolonged despite the largest dose of bupivacaine used (500 mg) allowing probably a significant prolongation of analgesia in the iliac crest site. Indeed, we previously showed that bupivacaine-loaded microspheres significantly increased the duration of motor blockade (8) in a brachial plexus sheep model (18). Similar results were observed with epidural administration of ropivacaine-loaded microspheres (19). Such drug delivery systems could be clinically interesting and could allow an association with regional anaesthesia without increasing the risk of systemic toxicity of local anaesthetics.

CONCLUSIONS

Infiltration of iliac crest harvest sites with local anaesthetics is an easy technique for postoperative analgesia. However, its effect last only 12 hours and does not show any reduction of the amount of morphine consumption in orthopaedic patients. The local anaesthetics infiltration produced a significant peak plasma level; such absorption must be taken into account if another infiltration or regional anaesthesia techniques are also used. Experimentally, local anaesthetic-loaded microspheres seem to be an interesting alternative to a catheter use to extend the beneficial effects of single infiltration.

References

1. Goulet J. A., Senunas L. E., DeSilva G. L., Greenfield M. L., *Autogenous iliac crest bone graft. Complications and functional assessment*, CLIN. ORTHOP., **339**, 76-81, 1997.
2. Todd B. D., Reed S. C., *The use of bupivacaine to relieve pain at iliac graft donor sites*, INT. ORTHOP., **15**, 53-5, 1991.
3. Heary R. F., Schleuk R. P., Sacchieri T. A., Barone D., Brotea C., *Persistent iliac crest donor site pain : independent outcome assessment*, NEUROSURGERY, **50**, 510-6, 2002.
4. Blumenthal S., Dullenkopf A., Rentsch K., Borgeat A., *Continuous ropivacaine infusion at the iliac crest donor site is an effective technique for postoperative analgesia*, ANESTHESIOLOGY, **102**, 392-7, 2005.
5. Le Guevello P., Le Corre P., Chevanne F., Le Verge R., *High-performance liquid chromatographic determination of bupivacaine in plasma samples for biopharmaceutical studies and application to seven other local anaesthetics*, J. CHROMATOGR., **622**, 284-90, 1993.
6. Estebe J. P., Lecacheur S., Le Naoures A., Leroy M., Ecoffey C., *Wound infiltration of iliac bone craft harvest site with ropivacaine*, ANESTHESIOLOGY, **93**, A878, 2000.
7. Dunstan S. P., Korczak P. K., *Use of epidural catheter for postoperative pain relief for bone harvesting from iliac crest*, BR. J. ORAL. MAXILLOFAC. SURG., **34**, 436-7, 1996.
8. Estebe J. P., Le Corre P., Du Plessis L., *et al.*, *The pharmacokinetics and pharmacodynamics of bupivacaine-loaded microspheres on brachial plexus block in a sheep*, ANESTH. ANALG., **93**, 447-55, 2001.
9. Heckman J. D., Ehler W., Brooks B. P., *et al.*, *Bone morphogenetic protein but not transforming growth factor- β enhances bone formation in canine diaphysial nonunions implanted with a biodegradable composite polymer*, J. BONE JOINT. SURG. AM., **81**, 1717-29, 1999.
10. Le Corre P., Estebe J. P., Clement R., *et al.*, *Spray-dried bupivacaine-loaded microspheres : in vitro evaluation, and biopharmaceutics of bupivacaine following brachial plexus administration in sheep*, INT. J. PHARM., **238**, 191-203, 2002.
11. Hoard M. A., Bill T. J., Campbell R. L., *Reduction in morbidity after iliac crest bone harvesting : the concept of preemptive analgesia*, J. CRANIOFAC. SURG., **9**, 448-51, 1998.
12. Cowan N., Young J., Murphy D., Bladen C., *Double-blind, randomized, controlled trial of local anesthetic use for iliac crest donor site pain*, J. NEUROSCI. NURS., **34**, 205-10, 2002.
13. Ahlmann E., Patzakis M., Roidis N., Shepherd L., Holtom P., *Comparison of anterior and posterior iliac crest bone grafts in terms of harvest-site morbidity and functional outcomes*, J. BONE JOINT. SURG. AM., **84**, 716-20, 2002.
14. Guinet P., Estebe J. P., Ratajczk M., Banssard J. Y., Chevanne F., Beck D., Le Corre P., Wodey E., Ecoffey C., *Electrocardiographic and hemodynamic effects of intravenous infusion of bupivacaine, ropivacaine, levobupivacaine, and lidocaine in anesthetized sheep*, REG. ANESTH. PAIN MED., **34**, 17-23, 2009.
15. Gundes H., Kilickan L., Gurkan Y., Sarlak A., Toker K., *Short- and long-term effects of regional application of morphine and bupivacaine on the iliac crest donor*, ACTA ORTHOP. BELG., **66**, 341-4, 2000.
16. Reuben S. S., Vieira P., Faruqi S., Verghis A., Kilaru P. A., Maciolek H., *Local administration of morphine for analgesia after iliac bone graft harvest*, ANESTHESIOLOGY, **95**, 390-4, 2001.
17. Puri R., Moskovich R., Gusmorino P., Shott S., *Bupivacaine for postoperative pain relief at the iliac crest bone graft harvest site*, AM. J. ORTHOP., **29**, 443-6, 2000.
18. Estebe J. P., Le Corre P., Chevanne F., Cathelineau G., Le Verge R., Ecoffey C., *Motor blockade by brachial plexus block in the sheep*, ANESTHESIOLOGY, **93**, 291-3, 2000.
19. Ratajczak-Enselme M., Estebe J. P., Wodey E., Malinovsky J. M., Chevanne F., Dollo G., Ecoffey C., Le Corre P., *Epidural, intrathecal and plasma pharmacokinetic study of epidural ropivacaine-loaded-PLGA microspheres in a sheep model*, EUR. J. PHARM. BIOPHARM., **72**, 54-61, 2009.